

Result Down's syndrome screening

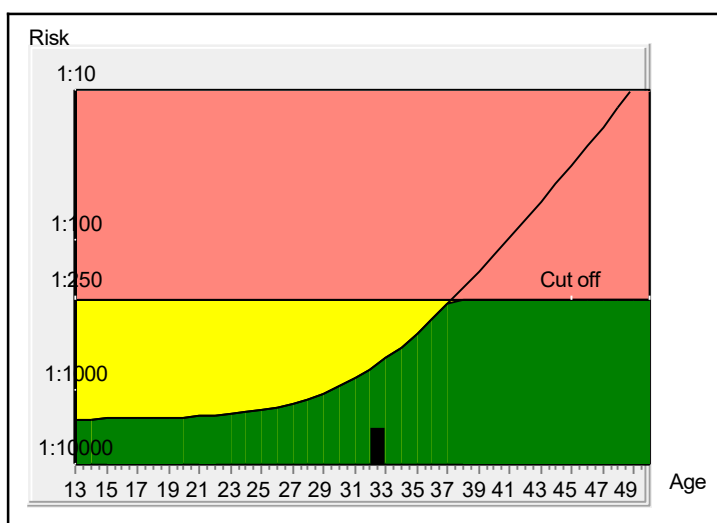
| | | | | |
|------------|------------------|---------------------------------|------------|---------------------|
| Name | Sample no | 2503031239/NOD | IVF | no |
| | MRS. PRACHI | Weight | 51 kg | Smoking |
| Patient ID | 2503031239/NOD | Fetuses | 1 | diabetes |
| | | Birthday | 18/02/1993 | Ethnic origin |
| Doctor | JITM Diagnostics | Age at delivery | 32.5 | Day of serum taking |
| | | Previous trisomy 21 pregnancies | no | Date of report: |
| | | | | 17/03/2025 |

Corrected MoM's and calculated risks

| | | | |
|-------|--------------|------|-----------|
| AFP | 77.5 ng/ml | 1.50 | Corr. MoM |
| HCG | 25104 mIU/ml | 0.90 | Corr. MoM |
| uE3 | 2.29 ng/ml | 1.42 | Corr. MoM |
| Inh-A | 227 pg/ml | 1.38 | Corr. MoM |

Ultra sound data

| | | | |
|--|------------|--------------------------------|-------------------|
| Day of ultra sound | 10/02/2025 | Nuchal translucency | 1.2 mm |
| | | | 0.69 MoM |
| CRL | 68.8 mm | Nasal bone | present |
| Gestational age by CRL | 13 + 0 | Measured by | DR. NEERJA CHOPRA |
| Gestation age on the day of serum taking | 18 + 0 | Qualifications in measuring NT | M.D |



Biochem. risk + NT
at term
 $< 1:10000$

Age risk
at term
1:683

TRISOMY 18 SCREENING

The calculated risk for trisomy 18 (with nuchal translucency) is $< 1:10000$, which represents a low risk.

NEURAL TUBE DEFECTS (NTD) SCREENING

The corrected MoM AFP (1.50) is located in the low risk area for neural tube defects.

The patient combined risk presumes the NT measurement was done according to accepted guidelines (Prenat Diagn 18: 511-523 (1998)).

The laboratory can not be hold responsible for their impact on the risk assessment ! Calculated risks have no diagnostic value!

below cut off
 Below Cut Off, but above Age Risk
 above cut off