

Result Down's syndrome screening

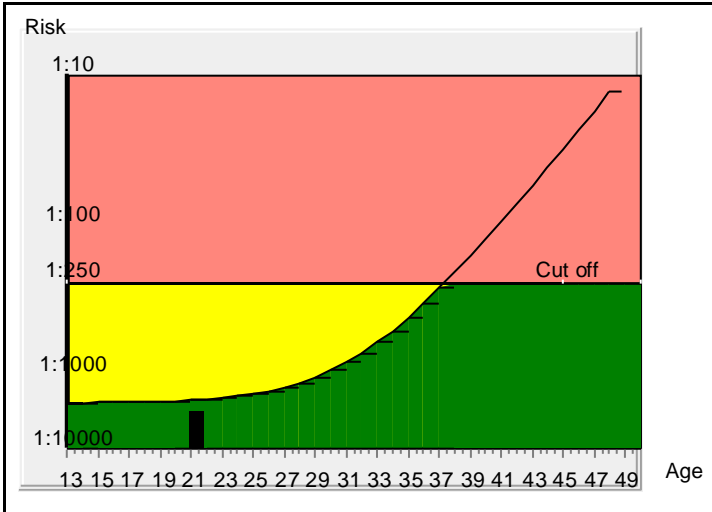
| | | | | |
|------------|----------------|---------------------------------|--------------------|-------------------------------|
| Name | MRS. REETU | Sample no | 2406013114/NOD IVF | no |
| Patient ID | 2406013114/NOD | Weight | 67.3 kg | Smoking no |
| Doctor | | Fetuses | 1 diabetes | no |
| | | Birthday | 16/07/2003 | Ethnic origin Asian |
| | | Age at delivery | 21.3 | Day of serum taking 7/06/2024 |
| | | Previous trisomy 21 pregnancies | no | Date of report: 8/06/2024 |

Corrected MoM's and calculated risks

| | | | |
|-------|-------------|------|-----------|
| AFP | 49.1 ng/ml | 1.21 | Corr. MoM |
| HCG | 9891 mIU/ml | 0.40 | Corr. MoM |
| uE3 | 1.58 ng/ml | 1.11 | Corr. MoM |
| Inh-A | 136.8 pg/ml | 0.97 | Corr. MoM |

Ultra sound data

| | | | |
|--|-----------|--------------------------------|------------------|
| Day of ultra sound | 6/05/2024 | Nuchal translucency | 1.3 mm |
| CRL | 71.8 mm | Nasal bone | 0.73 MoM present |
| Gestational age by CRL | 13 + 1 | Measured by | .. |
| Gestation age on the day of serum taking | 17 + 5 | Qualifications in measuring NT | .. |



Biochem. risk + NT at term <1:10000

Age risk at term 1:1511

TRISOMY 18 SCREENING
The calculated risk for trisomy 18 (with nuchal translucency) is < 1:10000, which represents a low risk.

NEURAL TUBE DEFECTS (NTD) SCREENING
The corrected MoM AFP (1.21) is located in the low risk area for neural tube defects.

The patient combined risk presumes the NT measurement was done according to accepted guidelines (Prenat Diagn 18: 511-523 (1998)).
 The laboratory can not be hold responsible for their impact on the risk assessment ! Calculated risks have no diagnostic value!

