

Result Down's syndrome screening

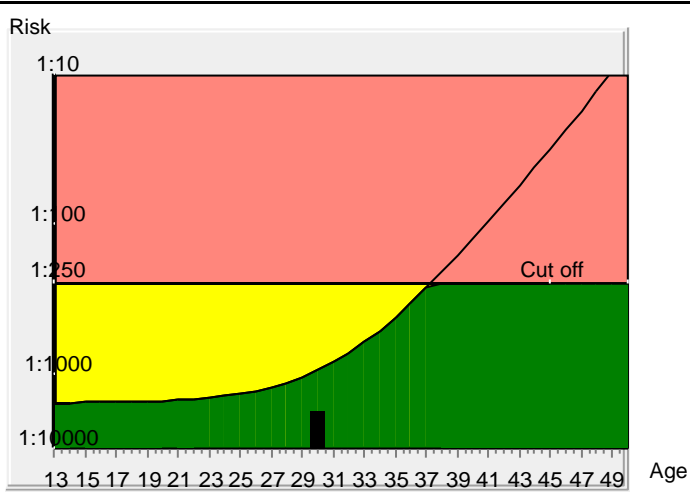
| | | | | |
|------------|--------------------|---------------------------------|--------------------------|----------|
| Name | MRS. SUKHDEEP KAUR | Sample no | 2406011026/NOD IVF | no |
| Patient ID | 2406011026/NOD | Weight | 67 kg Smoking | no |
| Doctor | | Fetuses | 1 diabetes | no |
| | | Birthday | 03/11/94 Ethnic origin | Asian |
| | | Age at delivery | 30.0 Day of serum taking | 06/06/24 |
| | | Previous trisomy 21 pregnancies | no Date of report: | 07/06/24 |

Corrected MoM's and calculated risks

| | | | |
|-------|--------------|------|-----------|
| AFP | 41.6 ng/ml | 1.06 | Corr. MoM |
| HCG | 24905 mIU/ml | 0.97 | Corr. MoM |
| uE3 | 1.4 ng/ml | 1.03 | Corr. MoM |
| Inh-A | 140 pg/ml | 0.98 | Corr. MoM |

Ultra sound data

| | | | |
|--|----------|--------------------------------|------------------|
| Day of ultra sound | 07/05/24 | Nuchal translucency | 1.3 mm |
| CRL | 71.2 mm | Nasal bone | 0.73 MoM present |
| Gestational age by CRL | 13 + 1 | Measured by | .. |
| Gestation age on the day of serum taking | 17 + 3 | Qualifications in measuring NT | .. |



Biochem. risk + NT
at term
<1:10000

Age risk
at term
1:962

TRISOMY 18 SCREENING

The calculated risk for trisomy 18 (with nuchal translucency) is < 1:10000, which represents a low risk.

NEURAL TUBE DEFECTS (NTD) SCREENING

The corrected MoM AFP (1.06) is located in the low risk area for neural tube defects.

The patient combined risk presumes the NT measurement was done according to accepted guidelines (Prenat Diagn 18: 511-523 (1998)).

The laboratory can not be hold responsible for their impact on the risk assessment ! Calculated risks have no diagnostic value!

